

EXAMGOOD

QUESTION & ANSWER

Exam Good provides update free of charge in one year!

Accurate study guides
High passing rate!

<http://www.examgood.com>

Exam : **CCRN Adult**

Title : CCRN (Adult) - Direct Care
Eligibility Pathway

Version : DEMO

1.A patient with a history of asthma presents with acute onset of dyspnea, a non-productive cough, and tachypnea. He is very anxious, restless, and tachycardic.

Which of the following is a first-line drug for these symptoms?

- A. leukotriene inhibitor
- B. anticholinergic
- C. mast cell stabilizer
- D. beta-agonist

Answer: D

Explanation:

Beta-agonists are the first-line drugs for acute asthma exacerbations because they rapidly reverse bronchoconstriction and improve airflow. They act by stimulating beta-2 receptors in the smooth muscle of the airways, causing relaxation and dilation. Beta-agonists can be administered by inhalation, nebulization, or injection. Examples of beta-agonists include albuterol, levalbuterol, and terbutaline.

Reference: Management of Acute Asthma Exacerbations | AAFP: This article states that "Quick-relief medicines include: Albuterol (ProAir HFA, Proventil-HFA, Ventolin HFA, others). Levalbuterol (Xopenex, Xopenex HFA)."

Asthma attack - Diagnosis and treatment - Mayo Clinic: This article states that "If you're in the yellow zone, the plan will tell you how many puffs of your quick-relief medicine to take and how often you can repeat the dose. Young children or people who have difficulty with an inhaler use a device called a nebulizer to inhale the medicine in a mist. Quick-relief medicines include: Albuterol (ProAir HFA, Proventil-HFA, Ventolin HFA, others). Levalbuterol (Xopenex, Xopenex HFA)."

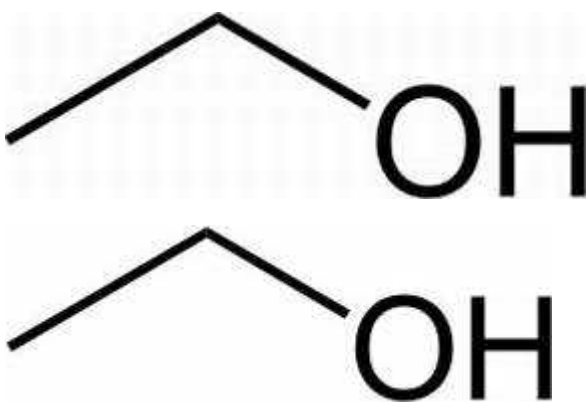
2.A patient is admitted with GI bleeding. During the assessment, the nurse notes the patient to be tremulous, anxious, and startles every time he is touched by the nurse.

Which of the following is the most pertinent part of the patient's history to obtain?

- A. last alcohol intake
- B. medication history
- C. time of last meal
- D. psychiatric history

Answer: A

Explanation:



Explore

Answer A

The patient's symptoms of tremulousness, anxiety, and startle response suggest that he may be

experiencing alcohol withdrawal, which can occur within hours to days after the last drink. Alcohol withdrawal can cause severe complications, such as seizures, delirium tremens, and death, if not treated promptly and appropriately. Alcohol withdrawal can also worsen GI bleeding by increasing gastric acid secretion, impairing clotting factors, and causing hypertension and tachycardia. Therefore, the most pertinent part of the patient's history to obtain is the last alcohol intake, which can help determine the risk and severity of withdrawal and guide the management of the patient.

Reference: Management of moderate and severe alcohol withdrawal syndromes: This article states that "Symptoms of alcohol withdrawal occur because alcohol is a central nervous system depressant. When a person drinks frequently, the brain compensates for alcohol's depressant effects by increasing the activity of excitatory neurotransmitters, such as norepinephrine, serotonin, dopamine, and glutamate, and reducing the activity of inhibitory neurotransmitters, such as gamma-aminobutyric acid (GABA). When alcohol intake is abruptly discontinued or reduced, this neuroadaptation is unmasked, resulting in a hyperexcitable state that is responsible for the characteristic withdrawal symptoms."

Alcoholic Gastritis: Causes, Symptoms and Treatment: This article states that "Alcohol Gastritis is a type of acute gastritis and is caused by excessive alcohol consumption. The sudden inflammation of the stomach lining can be very painful and cause severe stomach cramping, irritability and vomiting.

While consuming too much alcohol is the main cause of Alcohol Gastritis, it often develops in connection with some sort of infection, direct irritation or localized tissue damage. It can be caused by: Taking non-steroidal, anti-inflammatory medications like aspirin or ibuprofen (i.e., NSAIDs).

Certain bacterial infections. Bile reflux from proximal small intestine. Autoimmune disorders."

Can You Get Internal Bleeding from Alcohol Abuse: This article states that "Over time, alcohol abuse starts to eat away at the stomach lining. Continued drinking sets the stage for alcoholic gastritis to develop. Under these conditions, internal bleeding from alcohol abuse takes the form of blood oozing from stomach lines on an ongoing basis."

3.A patient's IV with norepinephrine (Levophed) infusing is red, swollen, and the IV pump is alarming. A nurse should anticipate

- A. administering phentolamine (Regitine).
- B. providing a warm compress.
- C. lowering the extremity below heart level.
- D. removing the IV immediately.

Answer: A

Explanation:

Phentolamine (Regitine) is the antidote for norepinephrine extravasation, which is the leakage of the vasopressor from the vein into the surrounding tissue. Phentolamine reverses the vasoconstriction and ischemia caused by norepinephrine by blocking the alpha-adrenergic receptors. Phentolamine should be administered intradermally around the site of extravasation as soon as possible, and the infusion should be stopped but the IV catheter should not be removed until some of the norepinephrine is aspirated. A warm compress may worsen the tissue damage by increasing the absorption of norepinephrine, and lowering the extremity may increase the edema and pain.

Removing the IV immediately may prevent the aspiration of norepinephrine and the administration of phentolamine.

Reference: Episode 240: What to do with norepinephrine extravasation: This article explains the steps to take when norepinephrine extravasates, including the use of phentolamine, and the reasons to avoid

cold compress, lowering the extremity, and removing the IV.

What are current recommendations for treatment of drug extravasation?: This article summarizes the latest recommendations for treatment of extravasation, and lists phentolamine as the immediate topical therapy for norepinephrine extravasation.

4. A patient who had a liver resection now has a copious amount of serous drainage from the surgical incision.

Which of the following should a nurse anticipate when caring for this patient?

- A. preparing for an incision and debridement of the wound
- B. applying several abdominal dressings
- C. administering antibiotics
- D. applying a drainage pouch to the site

Answer: B

Explanation:

A copious amount of serous drainage from a liver resection incision may indicate a bile leak, which can cause pain, infection, and delayed healing. The nurse should anticipate applying several abdominal dressings to absorb the fluid and protect the wound. The nurse should also monitor the patient for signs of infection, such as fever, increased white blood cell count, and foul-smelling drainage. The nurse should notify the surgeon of the excessive drainage and follow the orders for further interventions, such as imaging studies, drainage catheter placement, or surgical repair. Antibiotics may be prescribed, but they are not the first-line treatment for a bile leak. Incision and debridement of the wound may be necessary if there is necrotic tissue or infection, but it is not the initial action. Applying a drainage pouch to the site may not be sufficient to contain the large amount of fluid and may increase the risk of skin breakdown.

Reference: Problems after cancer surgery to remove part of your liver: This article states that "The bile ducts connect the liver and gallbladder to the small bowel. There is a risk of bile leaking from the ducts on the cut surface of the liver. This may cause pain, sickness and a high temperature. Rarely, you might need another operation to repair the leak."

Understanding Liver Abscess Treatment - Saint Luke's Health System: This article states that "The provider uses CT scan or ultrasound to help place the wire in the right spot. A thin, flexible tube (catheter) is then placed over the wire and into the abscess. The tube is left in place for 5 to 7 days to drain the fluid. In some cases, surgery may be done to cut into the liver abscess and drain it."

How Much Time Does it Take to Recover from Liver Surgery?: This article states that "If you have any drainage from your incision or if the area around your incision is puffy or red, visit your surgeon. Take a shower every day with warm water. When you are ready to take solid foods, make sure to eat 4 to 6 small meals every day. Do not lift heavy weights for 8 weeks after your surgery."

5. A patient is receiving therapeutic hypothermia post-cardiac arrest.

Which of the following orders should a nurse clarify?

- A. chemistry labs every day
- B. ABGs every 4 hours and with any ventilator changes
- C. hourly intake and output
- D. sequential compression devices

Answer: D

Explanation:

Sequential compression devices (SCDs) are not recommended for patients receiving therapeutic hypothermia (TH) post-cardiac arrest, because they may interfere with the cooling process and increase the risk of skin injury. SCDs are used to prevent deep vein thrombosis (DVT) by applying intermittent pneumatic pressure to the lower extremities, but they may also increase peripheral blood flow and heat exchange, which can counteract the effects of TH. SCDs may also cause skin breakdown, blisters, or burns in patients with impaired sensation and reduced perfusion due to TH. Therefore, a nurse should clarify the order for SCDs and consider alternative methods of DVT prophylaxis, such as pharmacological agents or early mobilization.

Reference: Therapeutic Hypothermia (TH) Education Components: This document states that “Avoid use of sequential compression devices (SCDs) during cooling phase as they may interfere with cooling process and increase risk of skin injury.”

Sequential Compression Devices: Clinical Effectiveness, Cost- Effectiveness and Guidelines: This document states that “One evidence-based guideline from the American Heart Association (AHA) and the American Stroke Association (ASA) recommended against the use of SCDs in patients undergoing therapeutic hypothermia after cardiac arrest, as they may interfere with the cooling process and increase the risk of skin injury.”